
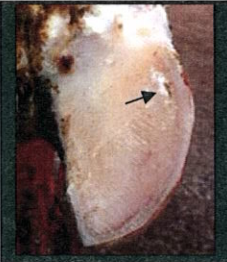






# BOVINE CLAW LESION IDENTIFICATION AND SEVERITY SCORE SHEET

	a = abscess White Line Abscess	b = bruise White Line Hemorrhage ('Bruise')	c = corn Interdigital hyperplasia ('Corns')	d = dermatitis Digital Dermatitis (Heel Warts)	e = erosion Heel Horn Erosion	f = fissure White Line Fissure
<b>Severity Score</b>						
<b>1 = mild</b>	Small amount of pus, but not extending to coronary band	Localized redness in white line of outer claw	Grape size growth between claws	Small dime size moist area in interdigital cleft	Small pock marks of erosion or small fissure	Small fissure in white line close to heel
						
<b>2 = moderate</b>	Large amount of pus, but does not emerge at coronary band	Diffuse redness in white line both claws	Larger than grape, but not touching ground	Strawberry granuloma larger than a dime	Single large fissure across entire heel	Wide fissure, but does not extend to coronary band
						
<b>3 = severe</b>	Pus emerging at coronary band	Diffuse hemorrhage with separation	Large tumor-like corn	Verrucose tentacles growing out of granuloma	Deep multiple fissures extending across heel with extensive erosion	Large fissure extending to coronary band without pus
						

Devised by Karl Burgi and Nigel B. Cook MRCVS



# BOVINE CLAW LESION IDENTIFICATION AND SEVERITY SCORE SHEET

	h = hemorrhage Sole Hemorrhage	p = phlegmon Interdigital Necrobacillosis (Foot Rot)	s = sole fracture Sole Fracture / Heel Ulcer	t = toe ulcer Toe Ulcer	u = ulcer Sole Ulcer	y = horizontal fissure Horizontal Fissure (Thimble)	g = digital sepsis Deep Digital Sepsis
Severity Score							
<b>1 = mild</b>	Superficial hemorrhage in typical site 	Slight separation of interdigital skin with little swelling 	Small fissure at junction of heel and sole not extending into heel 	Small fissure at white line in toe area 	Deep hemorrhage with exposure of corium less than dime area 	Small fissure on one claw 	Swelling around the coronary band of one claw 
<b>2 = moderate</b>	Localised deep hemorrhage in typical site 	Split in interdigital skin with swelling confined between claws 	Large fissure with underrun sole confined to heel area 	Disintegration of sole horn in toe area extending to corium 	Exposed corium more than a dime 	Small fissure on both inner and outer claw 	Toe ulcer with necrosis of the pedal bone 
<b>3 = severe</b>	Diffuse extensive hemorrhage across sole 	Deeply erosive lesion with swelling around the coronary band 	Separation of a large area of sole 	Widespread necrosis of corium in the toe without pedal bone involvement 	Prolapse of corium through full thickness defect 	Large fissure on both inner and outer claw within one inch of sole surface 	All deep digital sepsis lesions are severe and require veterinary attention 

Devised by Karl Burgi and Nigel B. Cook MRCVS